

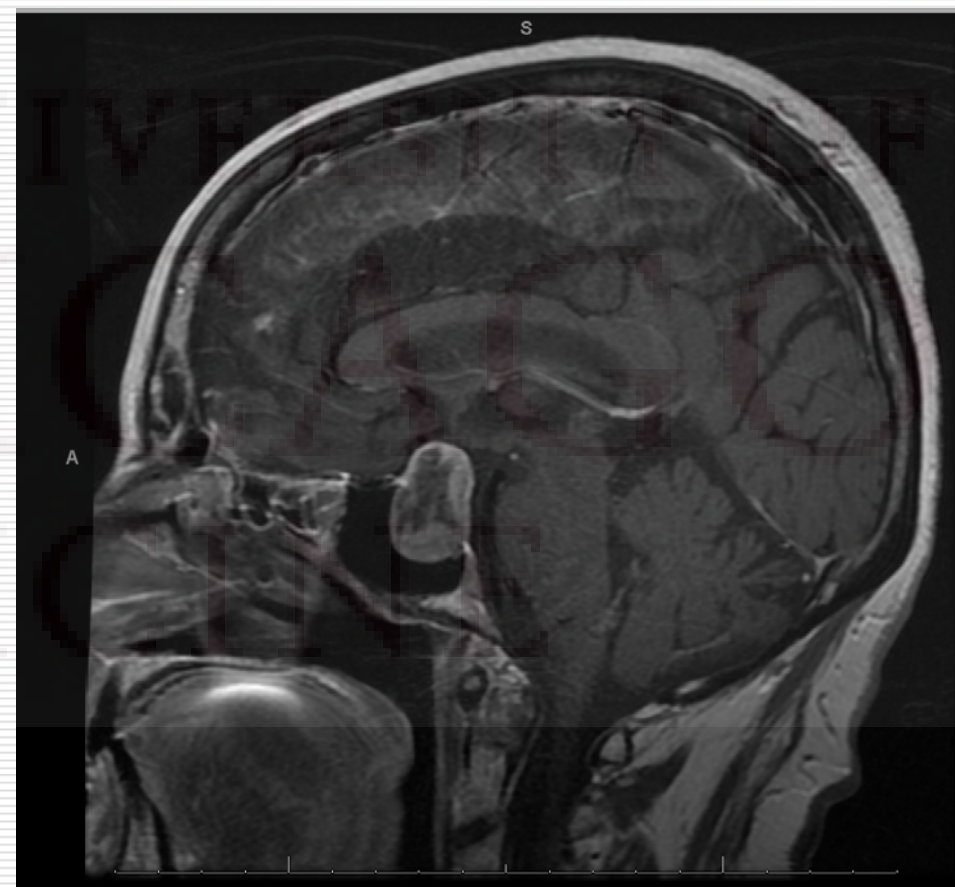
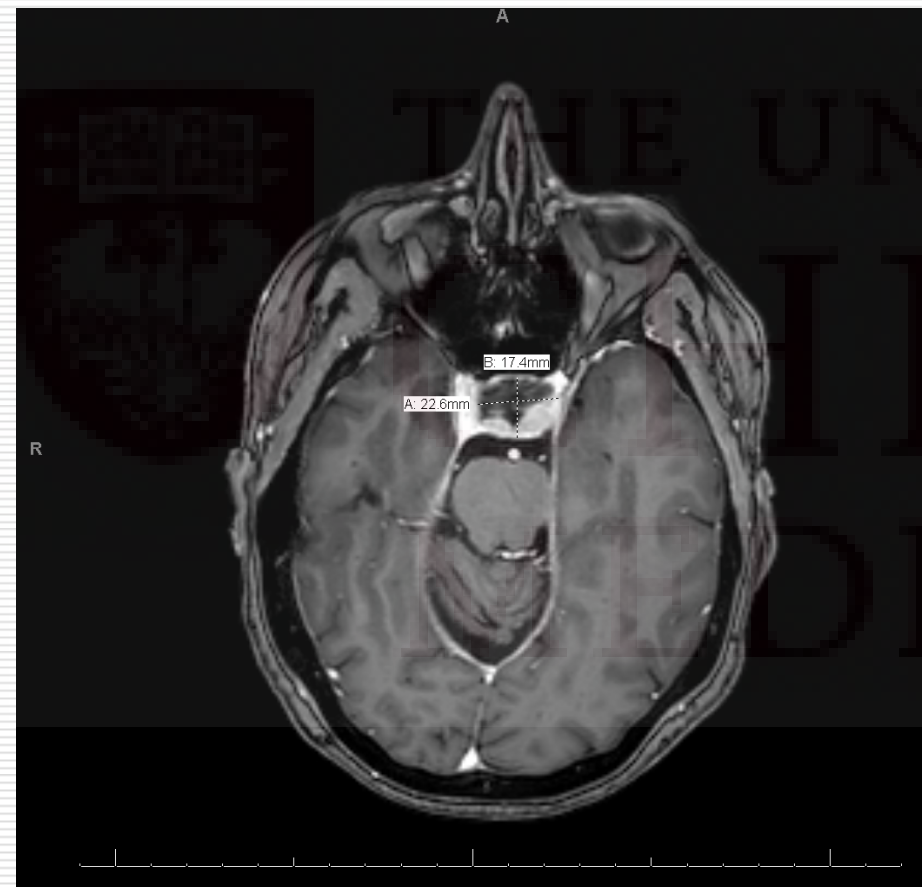
65 year old female with headaches and nausea

Olesya Krivospitskaya, MD and
Jamie Lee Steinmetz, MD (pathology)
Endorama 08/08/2013

HPI:

- ❑ 65 y.o. female presented with a c/o headaches and nausea for 4 months, which she attributed to a side effect of her sleeping pill.
 - ❑ Her PCP ordered head MRI, which showed a 23x17 mm mixed solid/cystic mass in the sellar and suprasellar region with a significant supracellar extension, compression to optic chiasm, invasion of the L cavernous sinus and possible invasion of the medial wall of the R cavernous sinus.
 - ❑ The pt was referred to neurosurgery
-

MRI:



PMH:

- **PMH:** DM2 (diagnosed 10 years ago, controlled on metformin and victoza), HTN, hypothyroidism (diagnosed 10 years ago), GERD, remote hx of breast cancer, s/p bilateral mastectomy, hyperlipidemia, depression, insomnia and anxiety
 - **Past surgical history:** total hysterectomy with bilateral oophorectomy at the age 39, bilateral mastectomy, cholecystectomy, adenectomy.
 - **FH:** Hypothyroidism in her daughter and sister, DM2 in her sister, mother, father, paternal grandparents, CAD in her father.
 - **SH:** Retired, no smoking, alcohol or illegal drugs.
-

Medications:

- Atenolol-chlorthalidone 50-25 mg/day
 - Atorvastatin 20 mg/day
 - Buspirone 10mg BID
 - Cholecalciferol 2000 IU/day
 - Cyanocobalamin 1000 mg/day
 - Dexlansoprazol 60 mg/day
 - Flaxseed 1000 mg BID
 - Folic acid 400 mcg/day
 - Iron 65mg BID
 - Levothyroxine 50 mcg/day
 - Victoza 1.8 mg/day
 - Metformin 1000 mg BID
 - Niacin 500 mg TID
 - Olmesartan 20 mg/day
 - Paroxetine 20 mg/day
 - Temazepam 30mg PRN for sleep
-

Review of systems:

- ❑ Constitutional: No fevers. No weight changes. **+ Fatigue.**
 - ❑ HEENT: No vision changes.
 - ❑ Cardiovascular: No chest pain. No palpitations.
 - ❑ Respiratory: No dyspnea. No orthopnea.
 - ❑ Gastrointestinal: **+ Nausea.** No diarrhea. No constipation.
 - ❑ Musculoskeletal: No myalgias.
 - ❑ Skin: No rash. No skin changes. No hair loss.
 - ❑ Neurologic: No tremor. No weakness. **+ Headaches.**
 - ❑ Psychiatric: **+ Depression. + Anxiety.**
 - ❑ Endo: No polyuria. No polydypsia.
-

Physical exam:

- ❑ Constitutional: Patient appears well-developed, well-nourished, in no acute distress.
 - ❑ HEENT:PERLA. No thyromegaly or nodules palpated.
 - ❑ Cardiovascular: Regular rhythm and rate. No murmurs appreciated. Intact distal pulses.
 - ❑ Respiratory/Chest: Normal respiratory effort. No wheezes or crackles.
 - ❑ Gastrointestinal/Abdomen: Normoactive bowel sounds. Soft, nontender, nondistended.
 - ❑ Musculoskeletal/extremities: No peripheral edema.
 - ❑ Neurological: AAOx3. Normal deep tendon reflexes. No cranial nerve deficit.
 - ❑ Skin: Skin is warm and dry. No acanthosis nigricans noted.
 - ❑ BP 135/80, Pulse 84, Temp 36.8 °C, Resp 19, Ht 167.6 cm (5' 6"), Wt 70.761 kg (156 lb), BMI 25.18 kg/m², SpO₂ 96%.
-

Labs:

132	94	25	130
3.5	24	1.1	

12.9	15.5	247
	44.2	

Ca 9.7 (8.4-10.2 mg/dL)

Mg 1.7 (1.6-2.5 mg/dL)

Phos 3.3 (2.5-4.4 mg/dL)

HA1C 6.4% (per patient report)

LFTs:

Total Protein 7.0 (6-8.3 g/dL)

Albumin 4.6 (3.5-6 g/dL)

Total Bilirubin 0.5 (0.1-1 mg/dL)

Alk Phos 79 (30-120 U/L)

AST 25 (8-37 U/L)

ALT 28 (8-35 U/L)

TSH 1.10 (0.3-4.0 mcU/ml)

Free T4 1.19 (0.9-1.7 ng/dL)

Total T3 56 (80-195 ng/dL)


Total T4 6 (5-11.6 mcg/dL)

ACTH 74 pg/dL at 3PM

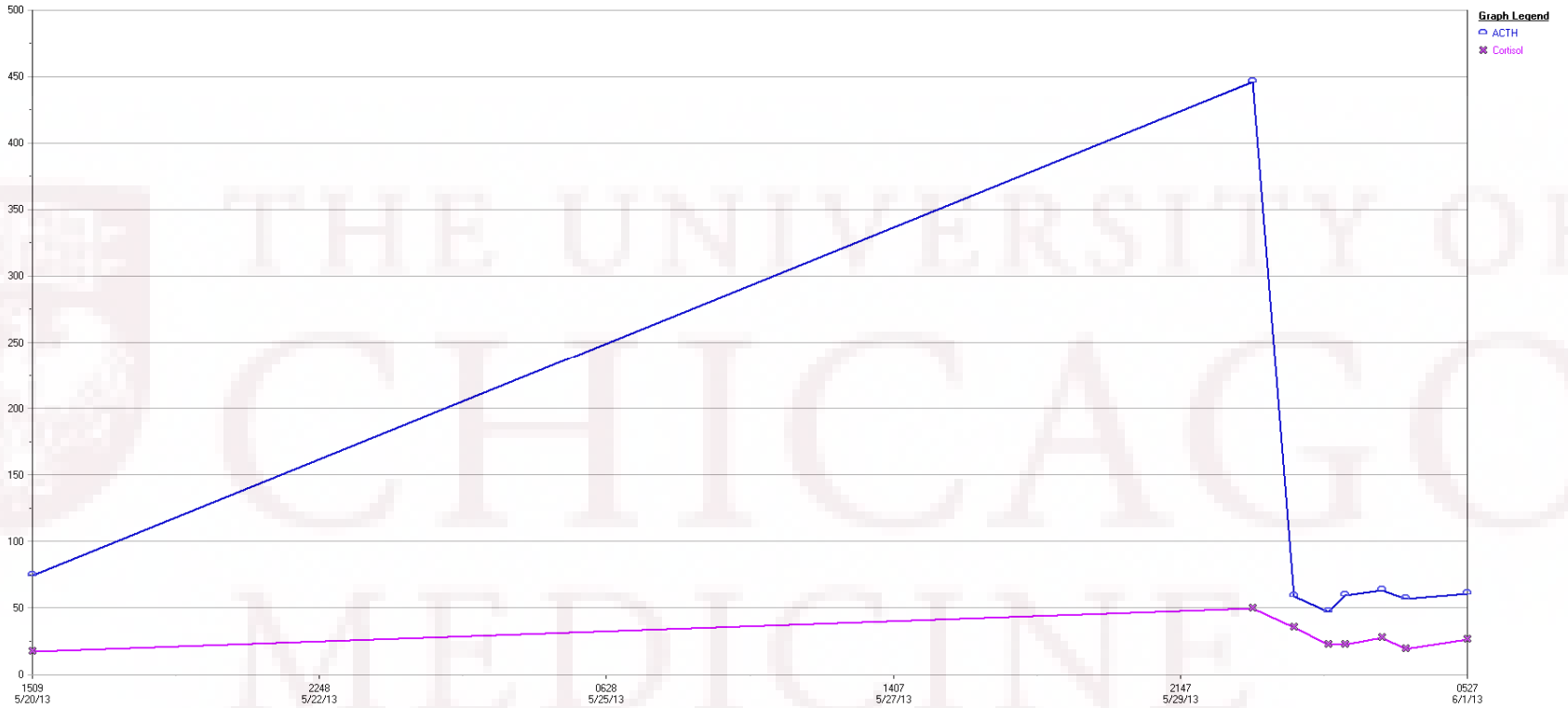
Cortisol 17.3 mcg/dL at 3PM

Prolactin 26.12 (4.8-23.3 ng/mL)

Growth hormone <0.1 (0-4.2 ng/mL) at 3PM

-
- 
- The patient underwent a transnasal/transsphenoidal resection of the tumor
-

Postoperative labs



	Ref. Range	5/20/2013 15:10	5/30/2013 11:49	5/30/2013 19:53	5/31/2013 02:34	5/31/2013 05:47	5/31/2013 13:00	5/31/2013 17:30	6/1/2013 05:27
ACTH	Latest Range: <52 pg/mL	74.0 (H)	446.0 (H)	58.8 (H)	47.2	59.5 (H)	63.0 (H)	56.6 (H)	60.7 (H)
Cortisol	No range found	17.3	49.6	35.6	22.1	22.3	27.3	18.9	26.3

Prolactin 15.78 (4.8-23.3 ng/mL)



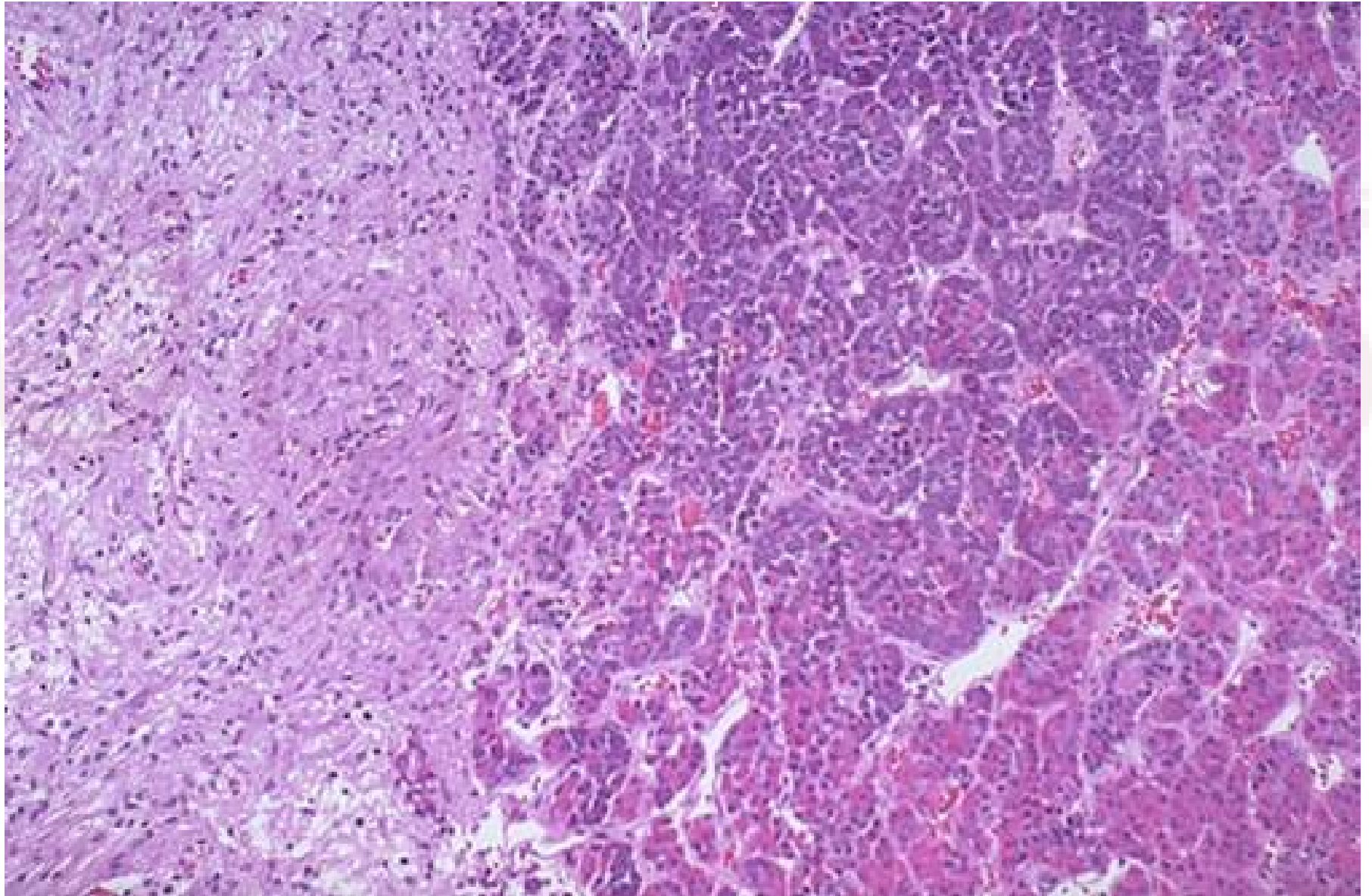
Pathology



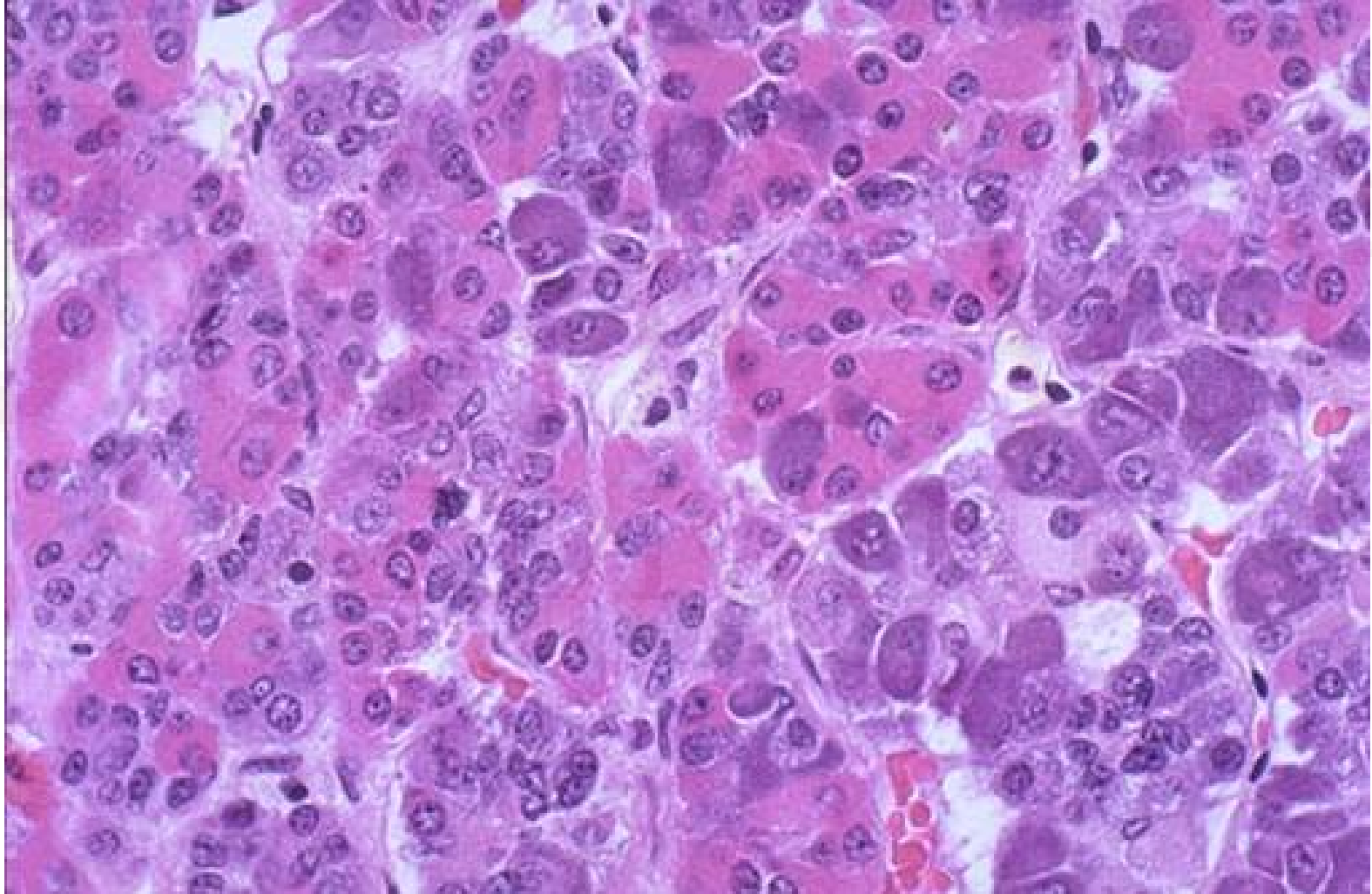
THE UNIVERSITY OF
CHICAGO
MEDICINE



Normal Pituitary

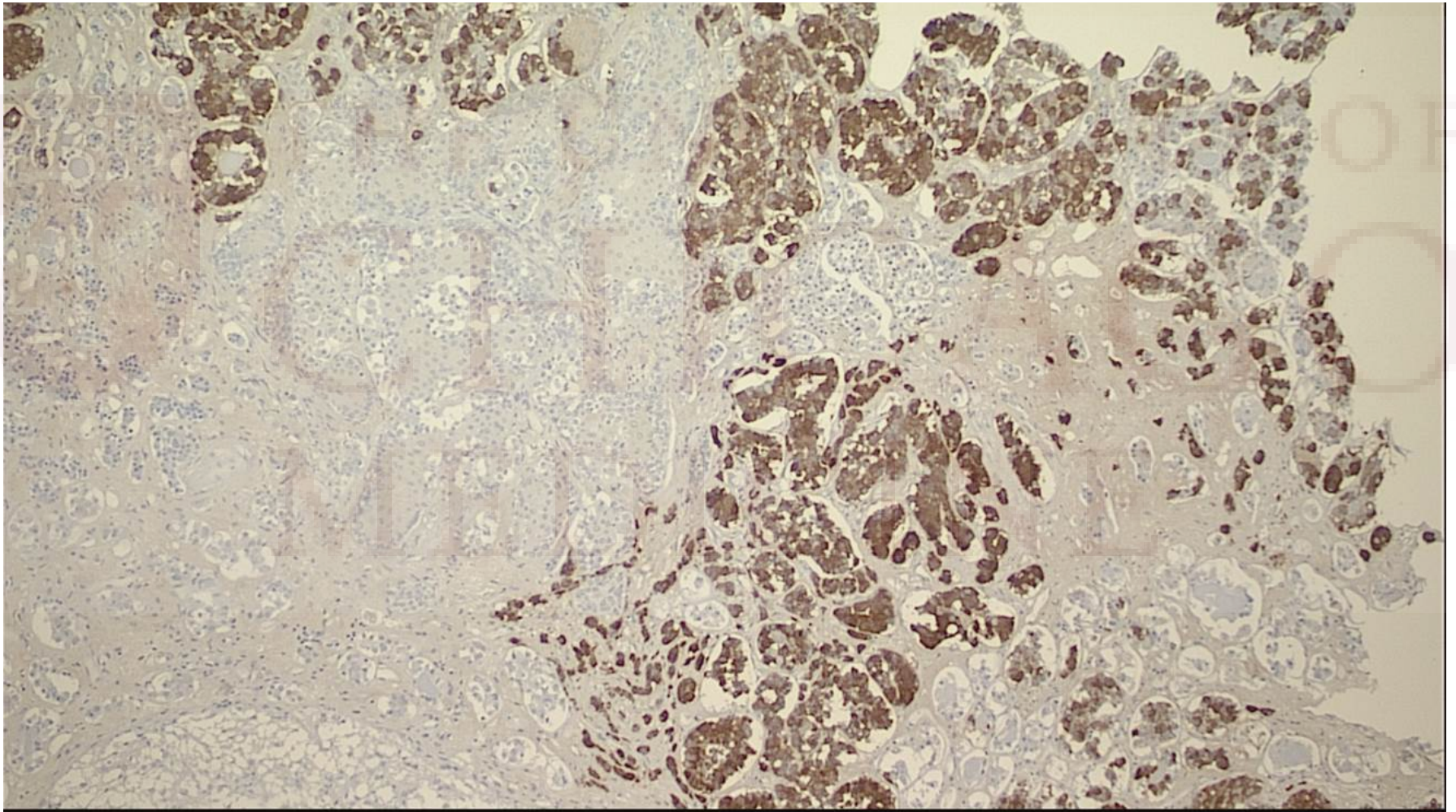


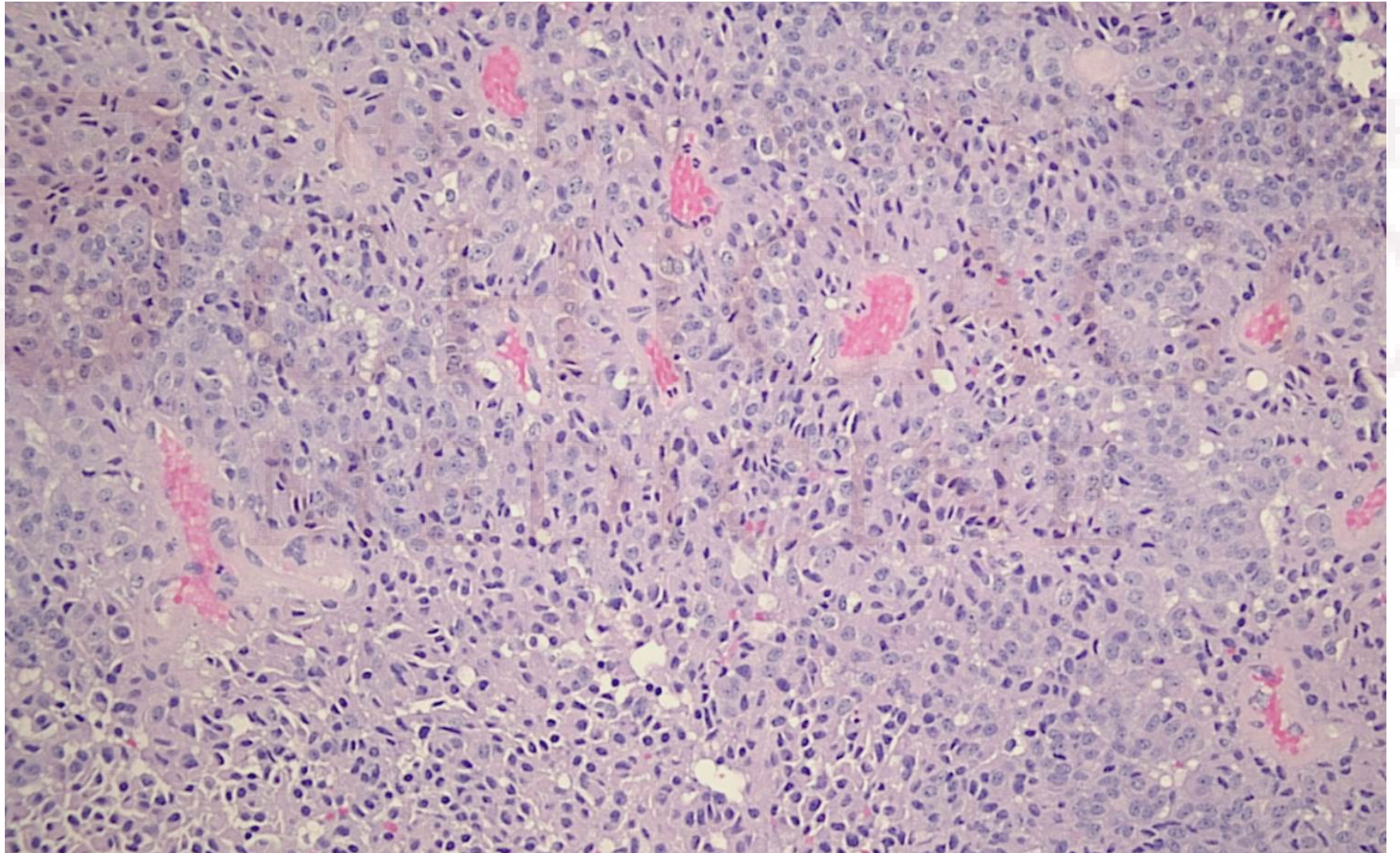
Normal anterior pituitary has a lobular architecture with a mixture of cell types

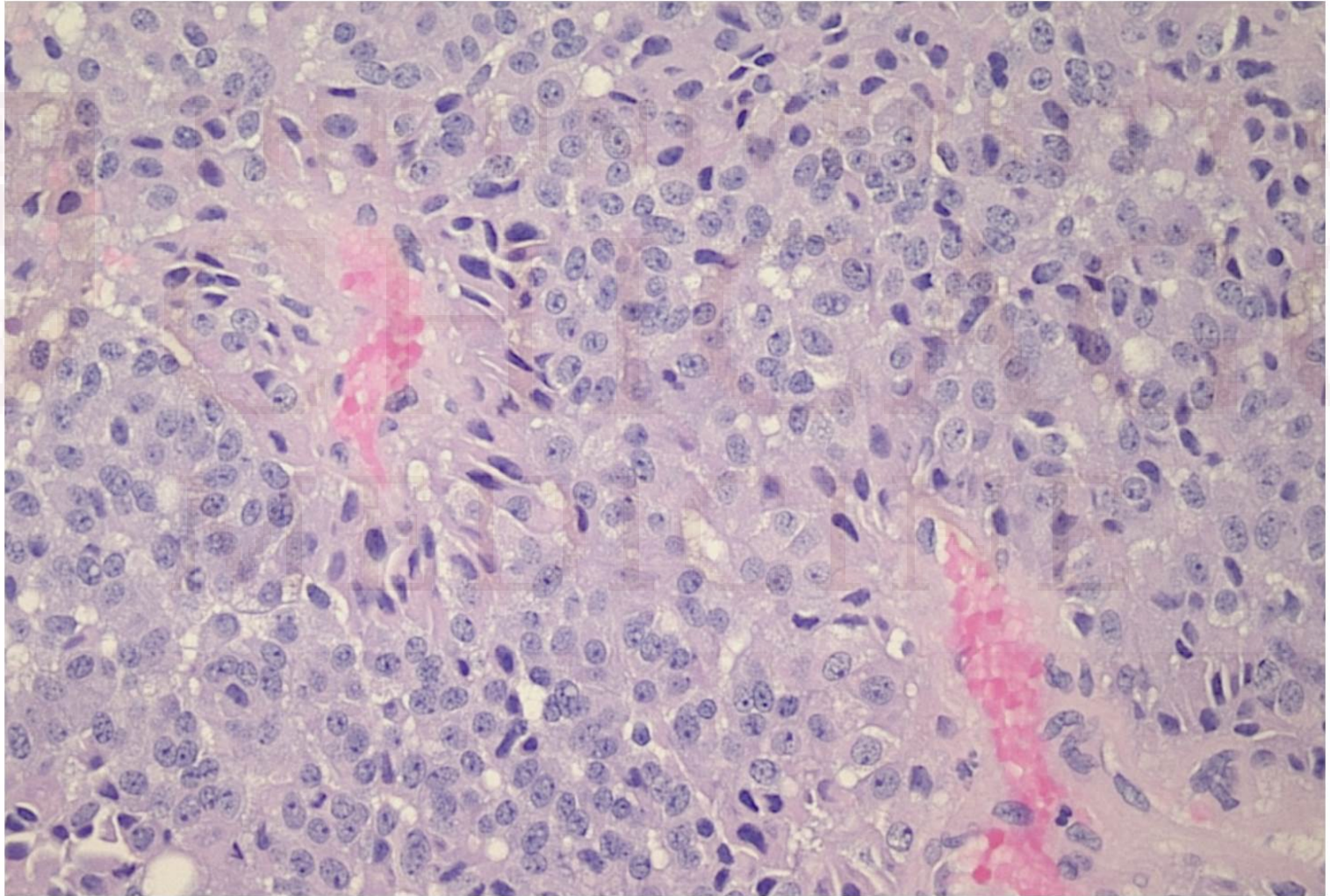




Normal staining for ACTH



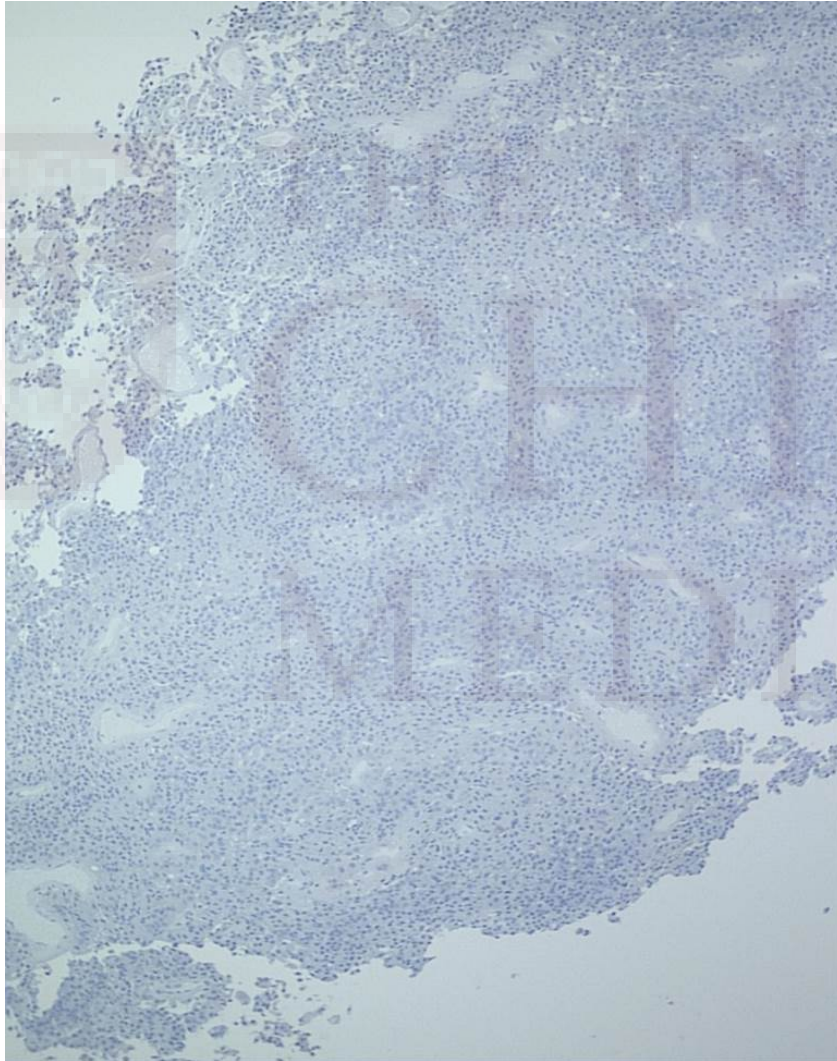




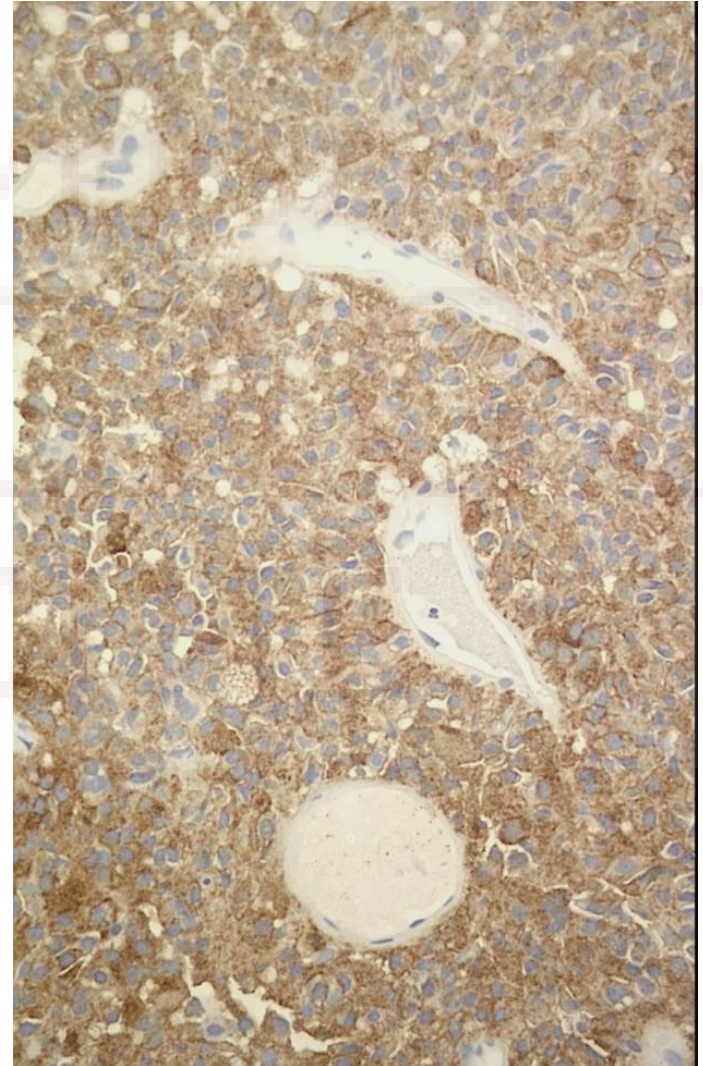
OF
O



IHC for TSH, prolactin,
FSH,LH and GH was
negative



IHC for ACTH was strongly positive



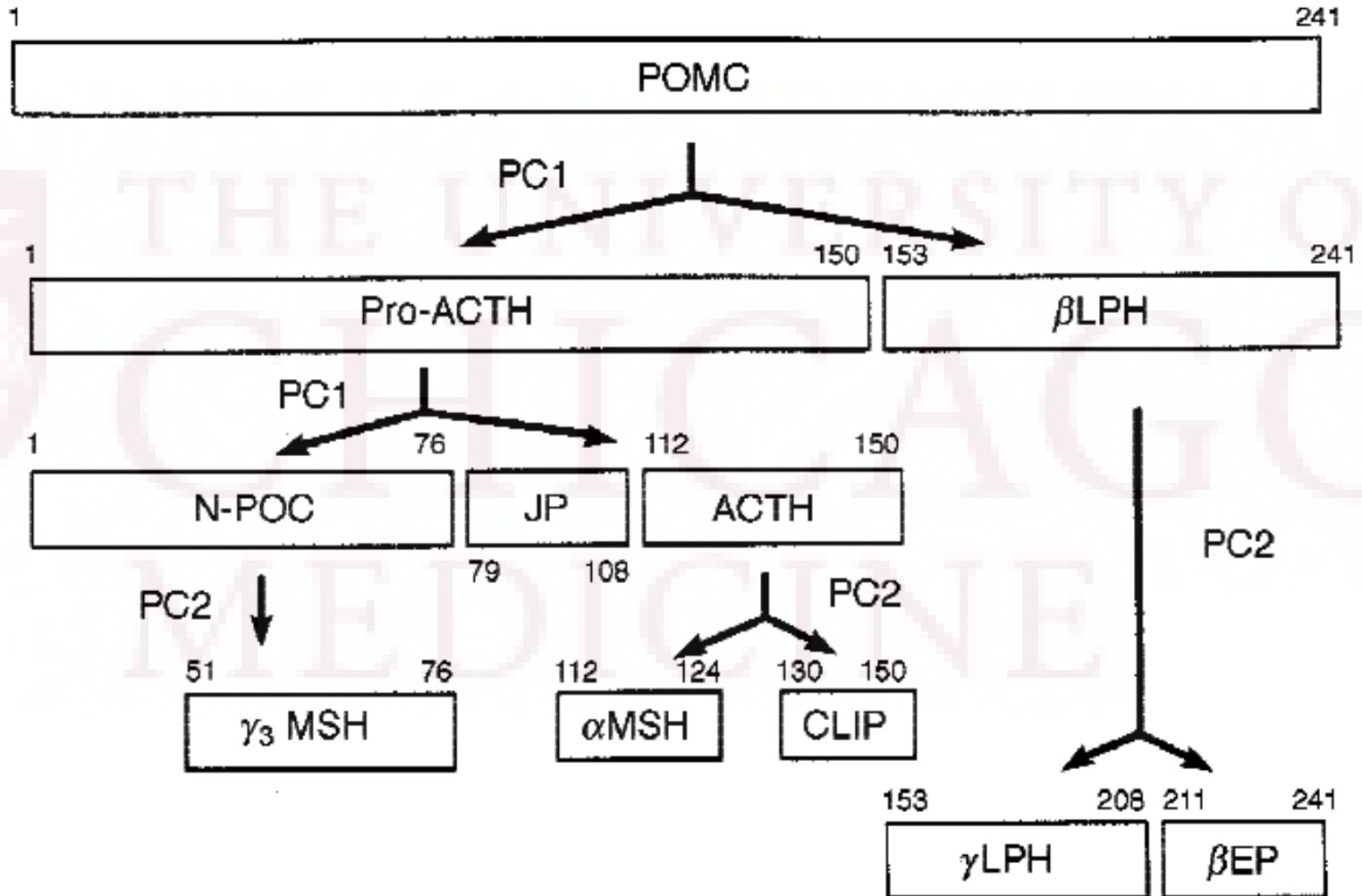
Corticotroph adenomas

- ~15% of all pituitary adenomas
- 3.5% of all adenomas are clinically silent but demonstrate ACTH staining with IHC
- Clinically silent adenomas can be composed of basophilic or chromophobic cells and are histologically identical to clinically active adenomas
 - The hormone product produced by the adenoma may be chemically aberrant or secreted intermittently and therefore not result in hypercortisolemia
- Silent corticotroph adenomas behave aggressively and have a high recurrence rate

-
- The patient is undergoing an evaluation at Evanston Hospital
 - The decision is to be made regarding radiation vs stereotactic radiosurgery
-

-
- ❑ What is biologically inactive ACTH?
 - ❑ What is silent corticotroph adenoma?
 - ❑ Do they carry a worse prognosis and higher recurrence rate?
-

POMC processing



Radioimmunoassay and chemiluminescent immunoassay

- two-site immunometric assay relies on two antibodies binding two different epitopes of the ACTH peptide. In general, antibodies have been raised to N and C-terminal regions of ACTH in order to ensure that ACTH 1-39 is detected rather than fragments derived from ACTH, such as α MSH and CLIP. Antibodies are radioactively or chemiluminiscently labeled.
 - Specificity is antibody dependent.
 - Have cross-reactivity with ACTH precursors (between 0.4% and 10% for pro-ACTH and $< 0.1\%$ for POMC for the in-house IRMA, other commercially available assay do not provide this information).
-

Limitations of assays:

- ❑ Some assay will report low levels of ACTH when the concentration of ACTH precursors is very high (such as in the ectopic ACTH syndrome, Nelson's syndrome and patients with large invasive pituitary macroadenomas).
 - ❑ Other assays will report high levels of ACTH due to cross reactivity with ACTH precursors.
 - ❑ Susceptible to „hook,, effect.
-

Silent corticotroph adenoma (SCA)

- pituitary tumors with positive immunohistochemical staining for corticotropin (ACTH) but without clinical evidence of excess cortisol
 - The majority of SCAs are macroadenomas upon presentation and secrete mostly biologically inactive, high-molecular-weight ACTH
-

Silent corticotroph adenoma (SCA)

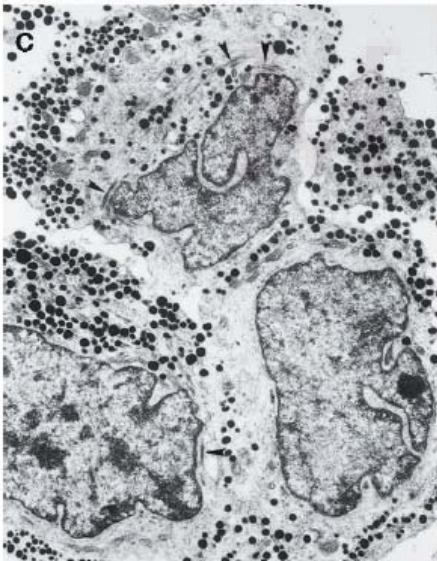
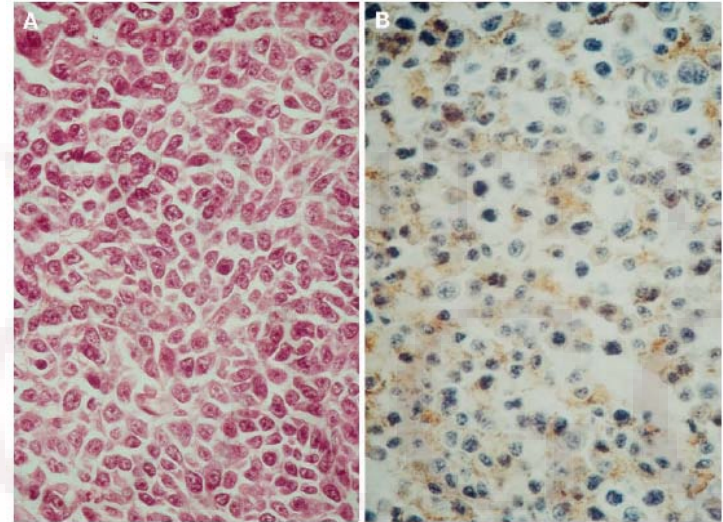
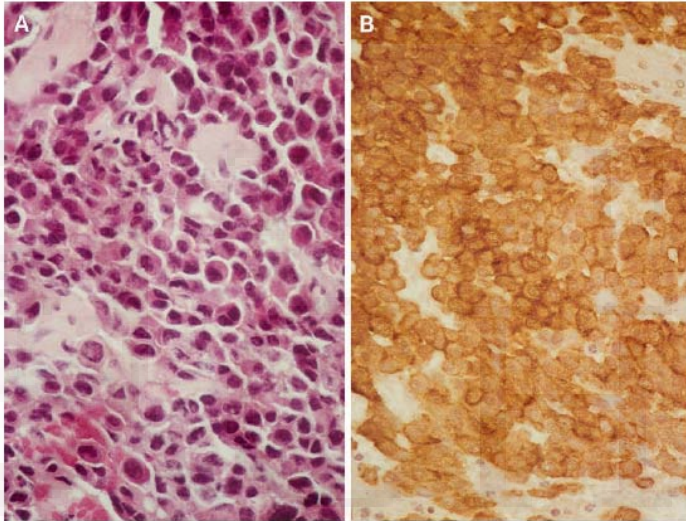
□ *subtype 1*

-- (basophilic, strongly periodic acid–Schiff positive, with strong and diffuse ACTH and b-endorphin immunoreactivity, similar to functional ACTH adenomas)

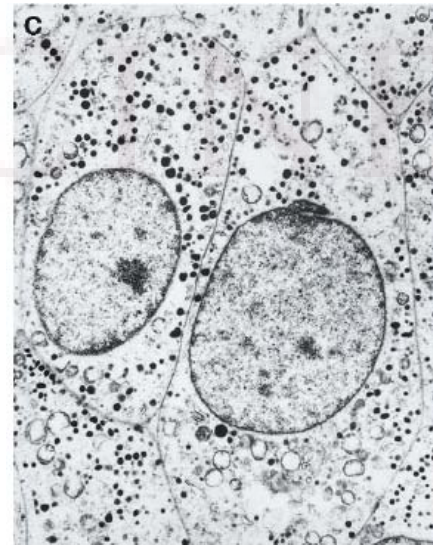
□ *subtype 2*

-- (chromophobic, weakly periodic acid–Schiff positive with scattered ACTH and b-endorphin immunoreactivity, and secretory granules in a characteristic teardrop shape on ultrastructural examination)

SCA subtype 1 and 2



Subtype 1



Subtype 2

TABLE 2. Clinical Characteristics of Silent Corticotroph Adenomas

	Subtype I	Subtype II	<i>P</i> Values ^a
Age (yr) (mean, range)	47 (11–79)	51 (42–63)	
Sex ratio (M/F)	1.7:1	6:1	
Invasion (radiological or surgical)	2/16 (44%)	5/7 (71%)	0.23
Preoperative hyperprolactinemia	5/16 (31%)	0/6 (0%)	0.16
Preoperative hypopituitarism	9/16 (56%)	5/7 (71%)	0.50
Apoplexy	1/16 (6%)	1/7 (14%)	0.39
Postoperative pituitary failure	6/16 (38%)	6/6 (100%)	0.01
Persistence/recurrence ^b	5/18 (63%)	2/5 (40%)	0.63

Scheithauer BW, Jaap AJ, Horvath E, Kovacs K, Lloyd RV, Meyer FB, Laws ER Jr, Young WF Jr. Clinically silent corticotroph tumors of the pituitary gland. *Neurosurgery*. 2000 Sep;47(3):723-9; discussion 729-30.

TABLE 3. Clinical and Endocrinological Comparison of Adrenocorticotrophic Hormone-producing Pituitary Adenoma Variants

	Cushing's Adenoma	Silent Corticotroph Adenomas (Overall)
Age	Adolescence to young adulthood	11–79 yr (mean, 48 yr)
M/F	1:3	2:1
Symptoms	Cushing's syndrome	Mass effects (visual symptoms)
Recurrence/persistence	10%	57%
Apoplexy	No	9%
Serum adrenocorticotrophic hormone levels	Normal to moderately elevated	Low to mildly elevated
Serum/urinary cortisol levels	Elevated	Low to normal
Preoperative pituitary insufficiency	Very rare	35%
Tumor size	85% microadenoma, 15% macroadenoma	100% macroadenoma
Invasion (dura/bone)	10% microadenoma, 60% macroadenoma	50%
Hemorrhage, necrosis, or cyst formation	No	60%

Scheithauer BW, Jaap AJ, Horvath E, Kovacs K, Lloyd RV, Meyer FB, Laws ER Jr, Young WF Jr. Clinically silent corticotroph tumors of the pituitary gland. *Neurosurgery*. 2000 Sep;47(3):723-9; discussion 729-30.

Silent corticotroph adenomas: Emory University cohort and comparison with ACTH-negative nonfunctioning pituitary adenomas.

Ioachimescu AG, Eiland L, Chhabra VS, Mastrogianakis GM, Schniederjan MJ, Brat D, Pileggi AV, Oyesiku NM.

Department of Medicine, Emory University, Atlanta, Georgia 30322, USA. aioachi@emory.edu

Abstract

BACKGROUND: Silent corticotroph adenomas (SCAs) are clinically nonfunctioning pituitary adenomas (NFPAs) with positive staining for corticotropin (ACTH) by immunohistochemistry. Whether SCAs behave more aggressively than NFPAs without ACTH immunoreactivity (ACTH negative) remains controversial.

OBJECTIVE: To compare characteristics and outcomes of SCAs with ACTH-negative NFPAs and to identify predictors of aggressive outcome. Primary composite endpoint included the first of any of the following events: progression, recurrence, or death.

METHODS: We reviewed all cases of SCAs and all ACTH-negative macroadenomas operated on between April 1995 and December 2007 by 1 neurosurgeon.

RESULTS: Our retrospective cohorts included 33 SCAs followed for 42.5 months (median) (range, 6.7-179.0 months) and 126 ACTH-negative patients followed for 42 months (range, 6-142 months). SCA were younger (mean \pm SD; 49.6 ± 14.1) than ACTH-negative patients (55.6 ± 12.8 , $P = .02$). Tumor diameter was similar (2.8 ± 1.0 cm); cavernous sinus invasion was present in 45.5% of SCAs and 30.2% of ACTH-negative NFPAs ($P = .09$). Postoperative tumor residual was detected in 53.1% of SCAs and 49.6% of ACTH-negative patients. Radiation was administered in 40.6% of SCAs at 16 months (range, 3-149 months) and 33.3% of ACTH-negative patients at 13 months (range, 3-94) postoperatively. Progression of residual tumor occurred in 24.2% of SCAs and 11.1% of ACTH-negative patients ($P = .08$); recurrence was similar (6.0% SCAs vs 5.5% ACTH-negative patients). Cumulative event-free survival rates were not significantly different between the 2 groups ($P = .3$). Age, sex, tumor size, cavernous sinus invasion, or SCA subtypes were not associated with outcome.

CONCLUSION: SCA patients were younger, but exhibited similar postoperative tumor regrowth rates as ACTH-negative macroadenomas while using a similar adjuvant radiation protocol. Long-term follow-up is warranted because predictors of regrowth are currently lacking.

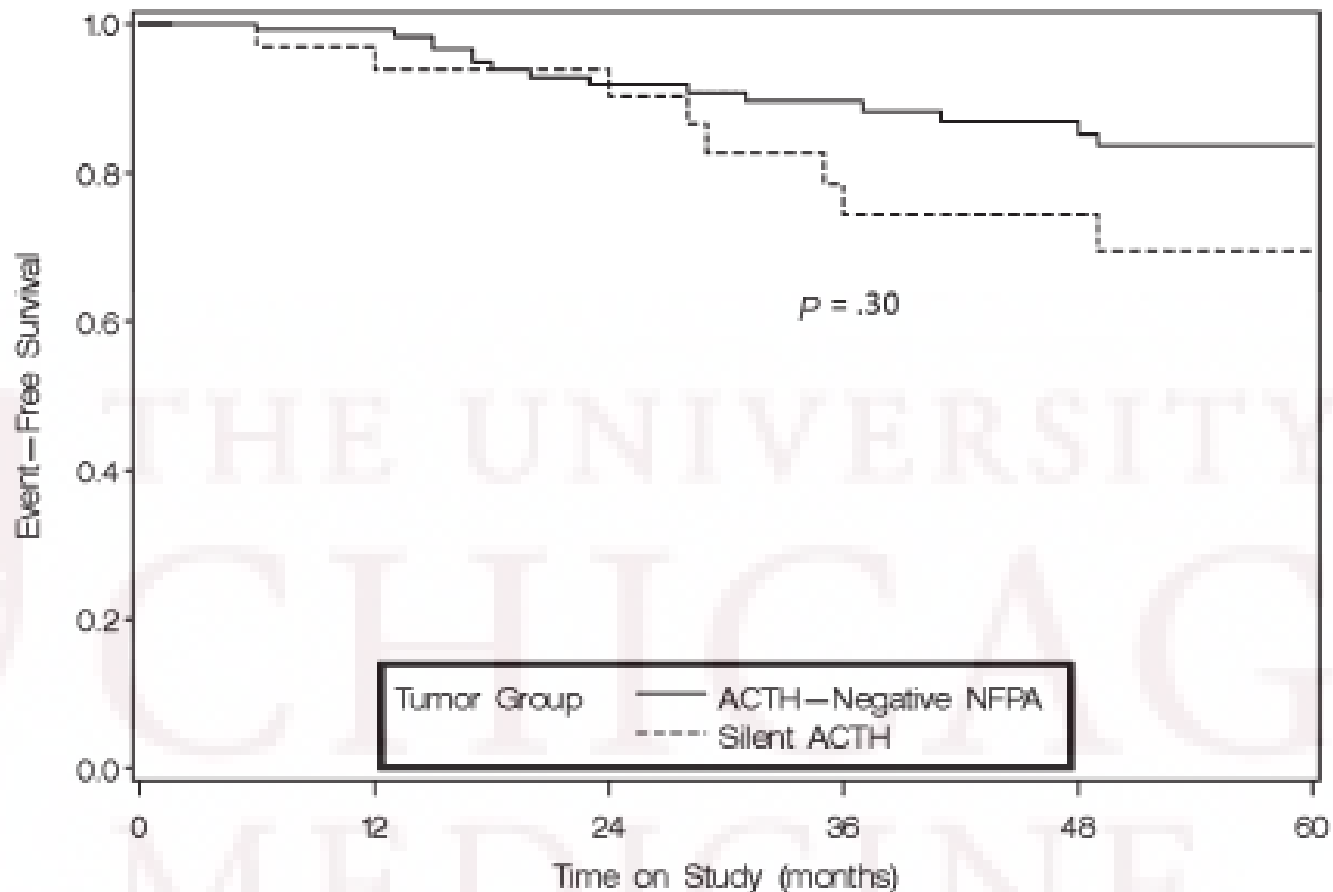


FIGURE 3. *Kaplan-Meier event-free survival in the silent corticotroph adenoma and corticotropin (ACTH)-negative nonfunctioning pituitary adenoma (NFPA) groups. Composite endpoint: tumor progression, tumor recurrence, and death.*

TABLE 2. Cumulative Estimates of Event-Free Survival According to Baseline Characteristics

Characteristics	No.	No. of Events	Estimates of Event-Free Survival, % (\pm SE)				P Value
			1 y	3 y	5 y	7 y	
Overall	159	38	98.1 \pm 1.1	86.1 \pm 3.1	80.4 \pm 3.8	63.5 \pm 6.5	
Tumor group							.30
<i>Silent ACTH</i>	33	13	93.8 \pm 4.2	74.4 \pm 8.5	69.5 \pm 9.2	46.3 \pm 12.5	
<i>ACTH negative</i>	126	25	99.2 \pm 0.8	89.6 \pm 3.0	83.7 \pm 4.0	70.0 \pm 7.2	
Sex							.72
<i>Male</i>	91	21	98.9 \pm 1.0	86.5 \pm 4.0	80.6 \pm 5.0	66.4 \pm 8.5	
<i>Female</i>	68	17	97.0 \pm 2.1	85.5 \pm 4.9	80.0 \pm 5.9	60.4 \pm 9.6	
Cavernous sinus invasion							.80
<i>Yes</i>	53	13	96.2 \pm 2.7	85.6 \pm 5.1	79.4 \pm 6.4	61.1 \pm 10.5	
<i>No</i>	106	25	99.1 \pm 0.9	86.0 \pm 4.0	80.6 \pm 4.8	64.9 \pm 8.1	

Ioachimescu AG, Eiland L, Chhabra VS, Mastrogianakis GM, Schniederjan MJ, Brat D, Pileggi AV, Oyesiku NM. Silent corticotroph adenomas: Emory University cohort and comparison with ACTH-negative nonfunctioning pituitary adenomas. *Neurosurgery*. 2012 Aug;71(2):296-303; discussion 304.

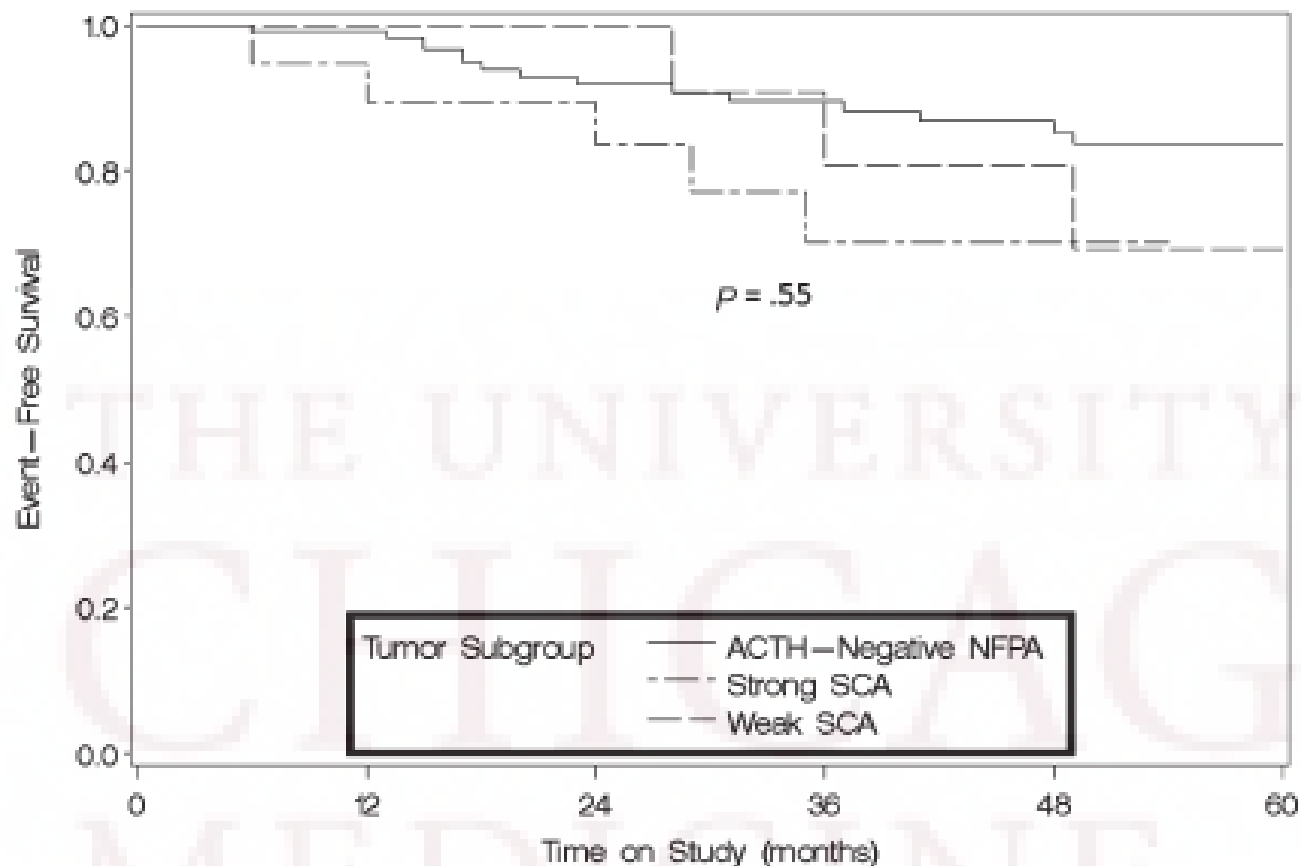
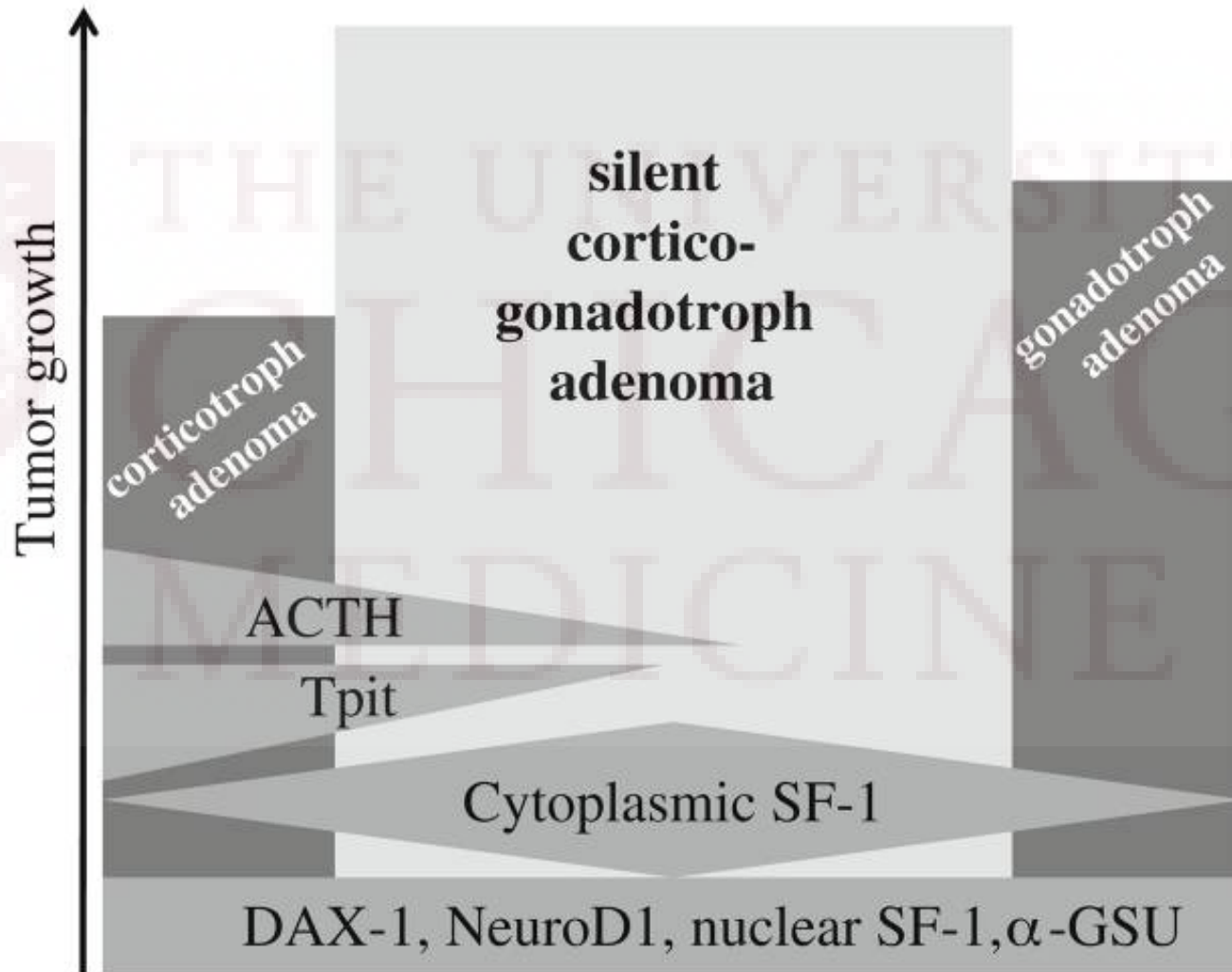


FIGURE 6. *Kaplan-Meier event-free survival in the weak silent corticotroph adenoma (SCA), strong SCA, and corticotropin (ACTH)-negative non-functioning pituitary adenoma (NFPA). Composite endpoint: tumor progression, tumor recurrence, and death.*

SCA express both corticotroph and gonadotroph transcription factors



Is clinical diagnosis possible?

- Some studies suggest exaggerated response to CRH and/or lysine-vasopressin and the lack of suppression of ACTH/cortisol secretion to opioid agonists

Take home points

- ❑ SCAs are macroadenomas that secrete mostly biologically inactive, high-molecular-weight ACTH
 - ❑ Currently used assays for ACTH measurement have limitations (inability to detect ACTH precursors by some assays, cross reactivity with ACTH precursors by other assays, hook effect)
 - ❑ SCA carry slightly higher recurrence rate and shorter overall survival
 - ❑ SCA express both corticotroph and gonadotroph transcription factors
 - ❑ Some studies suggest that clinical diagnosis could be possible
-

References

- Talbot JA, Kane JW, White A. Analytical and clinical aspects of adrenocorticotrophin determination. *Ann Clin Biochem.* 2003 Sep; 40(Pt 5):453-71.
 - Scheithauer BW, Jaap AJ, Horvath E, Kovacs K, Lloyd RV, Meyer FB, Laws ER Jr, Young WF Jr. Clinically silent corticotroph tumors of the pituitary gland. *Neurosurgery.* 2000 Sep; 47(3):723-9; discussion 729-30.
 - Ioachimescu AG, Eiland L, Chhabra VS, Mastrogianakis GM, Schniederjan MJ, Brat D, Pileggi AV, Oyesiku NM. Silent corticotroph adenomas: Emory University cohort and comparison with ACTH-negative nonfunctioning pituitary adenomas. *Neurosurgery.* 2012 Aug; 71(2):296-303; discussion 304.
 - Cooper O, Ben-Shlomo A, Bonert V, Bannykh S, Mirocha J, Melmed S. Silent corticogonadotroph adenomas: clinical and cellular characteristics and long-term outcomes. *Horm Cancer.* 2010 Apr; 1(2):80-92.
 - Ambrosi B, Colombo P, Bochicchio D, Bassetti M, Masini B, Faglia G. The silent corticotropinoma: is clinical diagnosis possible? *J Endocrinol Invest.* 1992 Jun; 15(6):443-52.
-